

Vet - Light

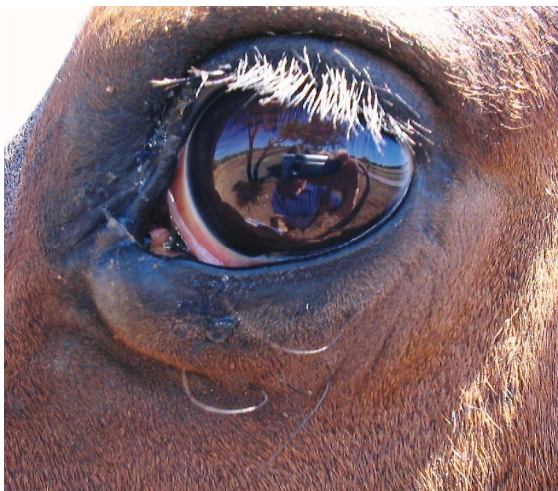

Case study: Habronema

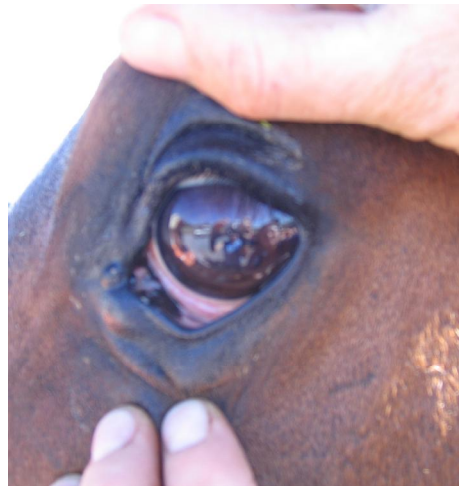
Patient history: Poon, a Boerperd gelding, presented with **severe Habronema granulomas**, especially around the left eye, causing **severe conjunctivitis, pain and lacrymation**.

Treatment: The Vet removed large pieces of caseous material and treated the gelding with Ivermectin, dexamethasone, terracortril suspension topically, and fly masks. The horse being in **severe pain** and with the eyes still **swollen** after the initial treatment, was difficult to work with. It was then decided to add Light Therapy once a day using the 100 mW probe on the **Tissue Trauma protocol**.

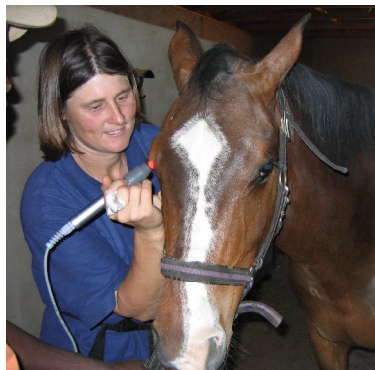
Outcome: After just **one treatment of light therapy the swelling had gone down and the horse was much easier to work with and the eye was far less painful**.



Presenting eye
Marked **swelling and inflammation**



1 light therapy session later
Decrease in swelling, inflammation and pain



Light Therapy was done once a day