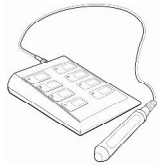

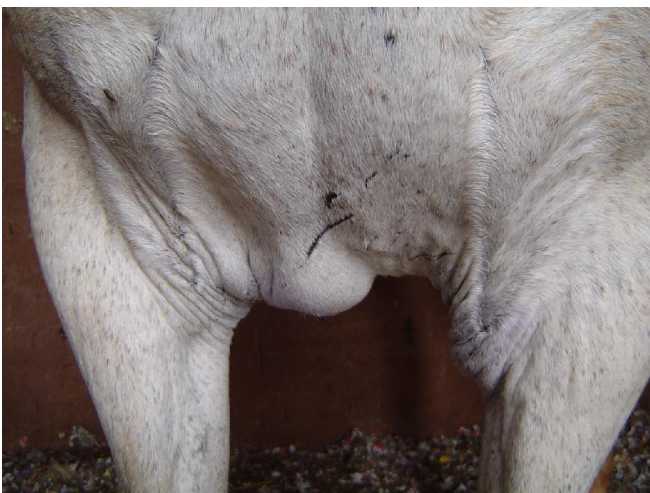Vet - Light



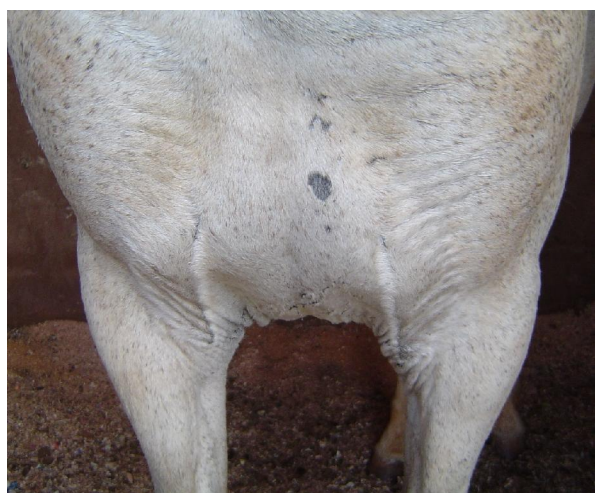
photizo
light therapy device

Case study: Edema / swelling

- Patient:** Violet, a 9 year old mare, presented with **marked swelling and pain** between her front limbs. The origin of the injury was assumed to be due to jumping over a fence as scratch marks were present at the site.
- Treatment:** Light therapy was done once a day using the Tissue Trauma protocol.
- Outcome:** **After only 4 light therapy sessions, the mare was sound without any swelling or pain.**



Presenting swelling / Edema between front limbs



4 Light therapy sessions later
No evidence of swelling